

A Man with Posterior Hip Pain

CME
CreditsTing-Yu Lin¹, Ke-Vin Chang^{2,3,4*}, Wei-Ting Wu^{2,3}, Levent Özçakar⁵¹Department of Physical Medicine and Rehabilitation, Lotung Poh-Ai Hospital, Lo-Hsu Medical Foundation, Inc., Yilan, Taiwan,²Department of Physical Medicine and Rehabilitation, National Taiwan University Hospital, College of Medicine, National Taiwan University, Taipei, Taiwan, ³Department of Physical Medicine and Rehabilitation, National Taiwan University Hospital, Bei-Hu Branch, Taipei, Taiwan,⁴Center for Regional Anesthesia and Pain Medicine, Wang-Fang Hospital, Taipei Medical University, Taipei, Taiwan,⁵Department of Physical and Rehabilitation Medicine, Hacettepe University Medical School, Ankara, Turkey

SECTION 1 – QUIZ

CASE

A 53-year-old male patient suffered from dull pain and intermittent numbness over his left buttock/thigh for the past 2 months. He denied back pain or subjective muscle weakness. He had an office job and did not have any recent trauma, sports participation, or prior local injury. Physical and neurological examination (including the range of motions, sensory, motor, and reflex testing) was unremarkable. Ultrasound examination was arranged to investigate the cause of unrelenting left posterior hip pain. What is your initial impression based on the ultrasound images [Figure 1]?

Declaration of patient consent

The authors certify that they have obtained all appropriate patient consent forms. In the form the patient has given his consent for his images and other clinical information to be reported in the journal. The patient understands that his name and initial will not be published and due efforts will be made to conceal identity, but anonymity cannot be guaranteed.

Financial support and sponsorship

This work was funded by the National Taiwan University

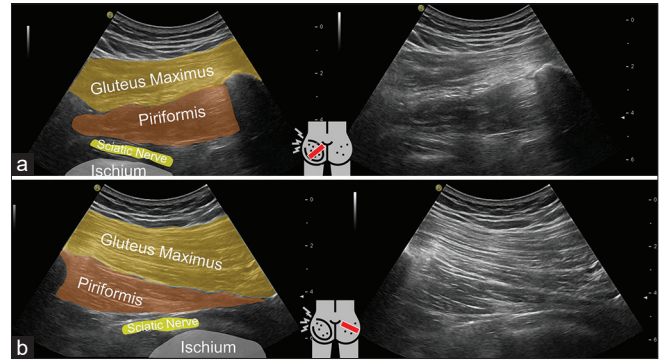


Figure 1: Ultrasound images of the posterior hip showed the left piriformis muscle (a) normal side (b)

Hospital, Bei-Hu Branch; Ministry of Science and Technology (MOST 106-2314-B-002-180-MY3 and 109-2314-B-002-114-MY3); and the Taiwan Society of Ultrasound in Medicine.

Conflicts of interest

Dr. Ke-Vin Chang, an editorial board member at *Journal of Medical Ultrasound*, had no role in the peer review process of or decision to publish this article. The other authors declared no conflicts of interest in writing this paper.

Address for correspondence:

Dr. Ke-Vin Chang,
Department of Physical Medicine and Rehabilitation, National Taiwan University Hospital, Bei Hu Branch and National Taiwan University College of Medicine, Taipei, Taiwan.
E-mail: kvchang011@gmail.com

Received: 17-08-2022 Revised: 18-09-2022 Accepted: 26-09-2022 Available Online: 07-12-2022

Access this article online

Quick Response Code:



Website:
<https://journals.lww.com/jmut>

DOI:
10.4103/jmu.jmu_81_22

This is an open access journal, and articles are distributed under the terms of the Creative Commons Attribution-NonCommercial-ShareAlike 4.0 License, which allows others to remix, tweak, and build upon the work non-commercially, as long as appropriate credit is given and the new creations are licensed under the identical terms.

For reprints contact: WKHLRPMedknow_reprints@wolterskluwer.com

How to cite this article: Lin TY, Chang KV, Wu WT, Özçakar L. A man with posterior hip pain. *J Med Ultrasound* 2024;32:281.